



**PATIENT**

Layla Larson

**SPECIES**

Canine

**BREED**

Rottweiler

**SEX**

Female Spayed

**AGE**

8.5 years

**WEIGHT**

82lbs

**INTERPRETED BY**

Maggie Machen Lamy,  
DVM, DACVIM  
(Cardiology)

**IMAGING PERFORMED BY**

Amanda Crook, SDEP

**HOSPITAL NAME**

River Edge Pet Medical  
Center

**REFERRING VET**

Dr. Young

**INVOICE**

47715

**DATE**

4/29/26

**PRESENTING CLINICAL SIGNS**

History: Presented on 4/9/26 for mass/cyst removal. Pre-op ECG noted 1st degree AV block, sinus arrhythmia (HR 86bpm), and left axis deviation. Advised atropine response test. Gave 0.04mg/kg atropine IV, waited 15min, and repeated ECG. HR 149bpm, 1st degree AV block persists despite administration of atropine, left axis deviation. Advised proceeding with cardiac workup prior to pursuing anesthesia. Intermittent GI upset, tenesmus +/- ptialism after defecation, reported recent lethargy/exercise intolerance by owner. On OTC Probiotics BID.

BP: 112, 124, 104, 110, 116mmHg.

Abnormal PE/Chem/CBC/UA Results (4/4/26): CBC/Chem 17/Lytes/Panc Lipase/TT4/UA, Eosinophilia 2.51k, otherwise all WNL. 4/9/26 - 4DX all neg. (4/10/26): FNA cytology (mass LH): cystic lesion w/ mild neutrophilic & eosinophilic inflammation, proliferation of basilar epithelial cells w/ mild atypia.

**ELECTROCARDIOGRAPHIC FINDINGS**

A six lead ECG is available at 25mm/s; 5mm/mV. The average heart rate is 100bpm. Brief HR stimulation to 150bpm towards the end of the tracing. The rhythm is sinus in origin, with a p for every QRS complex and vice versa. The P wave morphology is positive with a normal dimension. Prolonged PR. The QRS morphology is inverted with a splintered appearance. MEA is shifted left. No ectopic beats, pauses or dysrhythmias observed.

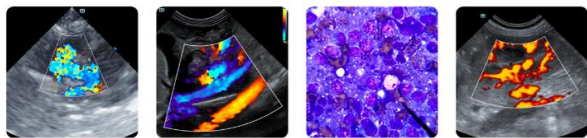
ECG diagnosis: Sinus rhythm with a left axis deviation and 1<sup>st</sup> degree AV block.

**ECHOCARDIOGRAM FINDINGS**

2D, m-mode, color flow and doppler imaging is available. Normal mitral valve leaflets with no prolapse into the left atrial lumen. Trivial mitral regurgitation with a normal left atrial dimension. Normal LV diameter with adequate myocardial function. The tricuspid valve appears normal with no tricuspid regurgitation. Normal right atrial and ventricular diameter and morphology indicating no overt evidence of pulmonary arterial hypertension. The pulmonic and aortic valves are normal in morphology and mobility. Normal pulmonic and aortic outflow velocities with laminar flow. No obvious aortic or pulmonic insufficiency. No pericardial or pleural effusion noted. No obvious cardiac masses.

**CARDIAC CHART**

CANINE CARDIAC PARAMETERS	MR VMAX (m/s)	TR VMAX (m/s)	LA/AO (Boon method)	LA/AO (Heart Base; Swe)	FS (%)	EF (%)	EPSS (cm)
NORMAL PARAMETER	4.5-5.5	<2.7	1.3	<1.6	28-40	40-100	<0.6
PATIENT	NA	NA	1.2	<1.4	33	60	0.38
CANINE CARDIAC PARAMETERS	HR (BPM)	AV VMAX (m/s)	PV MAX (m/s)	BODY WEIGHT (kg)	LA 2D short axis Base view (cm)	LVIDd Avg; 2D and m-mode short axis (cm)	LVIDs Avg; 2D and m-mode short axis (cm)
NORMAL PARAMETER	50-100	0.7-1.7	0.7-1.6	BELOW	BELOW	BELOW	BELOW
PATIENT	NM	1.5	0.9	37.2	NM	4.0	2.7
*Normal chamber parameters expressed as a mean value (SD)				3	1.27 (5.3)	2.46 (2.46)	1.36 (5.5)
				5	1.40 (4.5)	2.74 (5.2)	1.60 (4.7)



**PATIENT**

Layla Larson

**SPECIES**

Canine

**BREED**

Rottweiler

**SEX**

Female Spayed

**AGE**

8.5 years

**WEIGHT**

82lbs

**INTERPRETED BY**

Maggie Machen Lamy,  
DVM, DACVIM  
(Cardiology)

**IMAGING PERFORMED BY**

Amanda Crook, SDEP

**HOSPITAL NAME**

River Edge Pet Medical  
Center

**REFERRING VET**

Dr. Young

**INVOICE**

47715

**DATE**

4/29/26

**BODY WEIGHT DEPENDENT PARAMETERS**

*\*Note: All measurements based upon multi-modal images and methods. An average value is reported.*

Adapted from June Boon, Veterinary Echocardiography, 1998  
Rishniw M and Hollis NE, J Vet Intern Med 2000; 14:429-435  
Hansson et al, Vet Rad and Ultrasound 2002  
Bonagura et al. Echocardiography: principles of interpretation, Vet

10	1.50 (3.8)	3.27 (3.5)	2.06 (3.1)
15	1.83 (2.0)	3.71 (2.4)	2.43 (2.1)
20	2.02 (1.9)	4.14 (2.2)	2.80 (2.0)
25	2.18 (2.4)	4.48 (2.9)	3.10 (2.5)
30	2.33 (3.3)	4.83 (3.9)	3.39 (3.4)
35	2.48 (4.3)	5.17 (5.0)	3.69 (4.5)
40	2.62 (5.2)	5.48 (6.1)	3.96 (5.4)
50	2.88 (7.1)	6.07 (8.3)	4.46 (7.4)

**INTERPRETATION OF THE FINDINGS & FURTHER RECOMMENDATIONS**

Overtly normal cardiac dimensions and function, with no obvious dysfunction or dilation of the left heart. No significant valvular leaks are visualized, and no evidence of pulmonary hypertension.

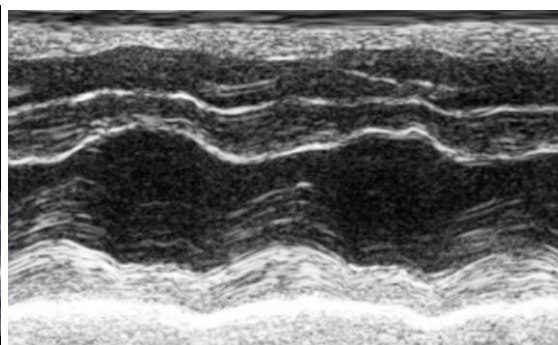
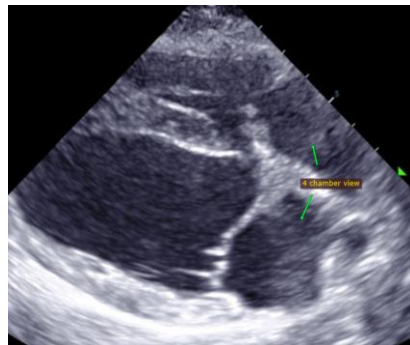
The ECG is similar to what is described previously, with a normal sinus for them, first degree AV block and a left axis deviation. The rhythm/AVB reportedly persisted despite atropine administration, although this is not documented here. A structural cause for this abnormality is not identified. Assuming the atropine challenge was administered appropriately as discussed in the report, this likely suggests AV nodal disease is likely present in this case and anesthesia becomes increased risk. While an increase in heart rate was documented with atropine, persistence of AV block increases risk for a lack of response to emergency heart rate stimulation if needed. Options at this point would include forego anesthesia at this time, referral to a facility with an anesthesiologist, or simply proceeding with caution if necessary. Certainly premeditating with a vagolytic would be indicated with close monitoring of heart rate and rhythm throughout the study.

Monitor for development of a heart murmur, cough, labored breathing, exercise intolerance or collapse episodes.

A recheck echocardiogram is recommended should a significant murmur develop, or signs of cardiac compromise be noted in the future.

Reassess an ECG in 6 months. Further arrhythmia work up may be indicated sooner if the patient experiences clinical signs such as syncope in the future.

**IMAGES**





## PATIENT

Layla Larson

## SPECIES

Canine

## BREED

Rottweiler

## SEX

Female Spayed

## AGE

8.5 years

## WEIGHT

82lbs

## INTERPRETED BY

Maggie Machen Lamy,  
DVM, DACVIM  
(Cardiology)

## IMAGING PERFORMED BY

Amanda Crook, SDEP

## HOSPITAL NAME

River Edge Pet Medical  
Center

## REFERRING VET

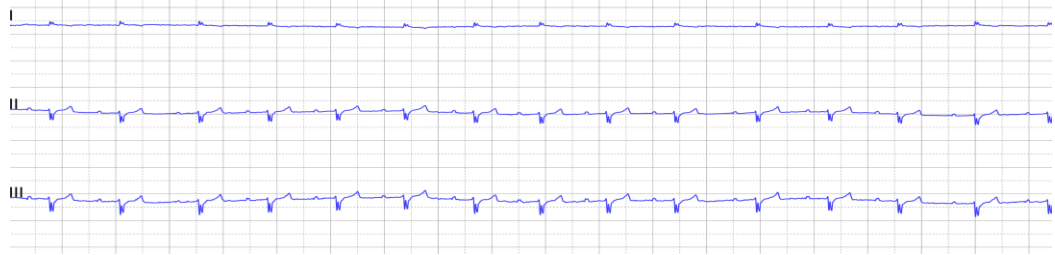
Dr. Young

## INVOICE

47715

## DATE

4/29/26



**The information and recommendations provided are based on the images presented by the referring veterinarian. No evaluation can be communicated regarding pathology that was not visible in the image/video clips provided.**

Thank you for this referral. This report was generated using transcription software, and minor dictation errors may be present. If the clinical or image interpretation does not parallel your findings or if I can be of any further assistance, please contact me.

**Maggie Machen Lamy, DVM**  
**Diplomate of the American College of Veterinary Internal Medicine (Cardiology)**  
info@sonopath.com